Boston University Chobanian & Avedisian School of Medicine
Physician Assistant Program

Prenatal Care Workshop – Patient Case #2 - Answers

Instructions: To do this case, you will need to assume that the date of the patient visit is January 2 of any year.

Patient History: 38-year-old G 4 P3, 1-0-2-1 cis-woman presents for prenatal care. Her LMP was June 3 and she has regular 28-day cycles. She states that she has had some leaking urine for the past day and feels that the baby may have dropped and is kicking her bladder which is causing the urine to leak. No contractions, spotting or bleeding.

PMH: S/P NSVD (normal spontaneous vaginal delivery) at 39 wks, 7lbs 12oz, female. Baby is now 3 years old and well.
S/P SAB (spontaneous miscarriage) at 8 weeks
S/P TOP (termination of pregnancy)

F**H:** Mother 63 Type II DM; Father died age 58 of MI; sister 23 with Type I DM and infertility; brother 28 with HTN

SH: Third grade teacher; lives with husband in old house which they are renovating

PE: height 5' 7", weight 160 lbs, BP 145/85, P 86, temp 98.9, RR 16, Point of care urine dipstick shows 2+ protein, neg glucose, negative white blood cells

Abdomen: soft, gravid, non-tender, fundal height is 30 cm with a palpable vertex presentation and the fetal heart rate is 144 bpm (normal 120-160 bpm)

Q1. Calculate her EDD: Based on her LMP, her EDC is 3/9/XXXX

Q2. What is her EGA on the date of the visit?
Her estimated gestational age (EGA) is 30 weeks 4 days. By convention, the weeks are always stated as weeks that are completed and then the days are added after the weeks.

Q3. In what trimester is she? Third trimester

Chart review: Looking back on her prenatal chart you see the following:

Date	Gestational Age	Weight	BP	Fundal Height	Urine Protein/glucose	Fetal heart
12/4	26	152	120/70	26	Neg/neg	142
12/22	28	154	118/68	28	Neg/neg	144
12/27	29	155	120/68	30	Neg/neg	140

1/2	30	160	145/85	30	2+/neg	144

Q4. Are there any parts of her history or exam today that concern you? Yes, there are two things to note.

A. Her reported **history of leaking urine** may suggest **ruptured membranes**. Since she is at 30 weeks this would be premature ruptured membranes (PROM). The report of "dropping" goes along with PROM too since loss of amniotic fluid causes the baby to be carried lower.

B. Her **BP is elevated**, her **weight is up 5 lbs in 1 week** and there is now **protein in her urine**; all are signs of PIH (pregnancy induced hypertension or pre-eclampsia). During her previous visits there were no positive findings.

C. **Leaking urine** may also suggest a urinary tract infection (UTI). While this is also a correct answer, the possibility of ruptured membranes is more concerning. The lack of white blood cells on the urine diptest would suggest that this is not a UTI.

Q5. What is your next step in the evaluation of this patient?

PROM – do a sterile speculum exam to check for evidence of amniotic fluid in the vagina. A sterile swab may be used to take sample and place on glass slide. Once dried, a fern like pattern confirms the fluid is ammonitic fluid.

PIH – Take her BP while she is lying on her left side. Left lateral decubitis position takes the pressure off the vena cava caused by the gravid uterus, improving venous return and lowering blood pressure.

6. What is the definition of PIH? What would be your treatment plan?

Definition = mild BP $\geq$ 140/90 but < 160/110 on 2 occasions 6 hours apart.

Severe BP $\geq$160 systolic or $\geq$ 110 diastolic on 2 occasions 6 hours apart.

Treatment: Her reflexes and pedal edema along with the presence or absence of clonus should be recorded. Patients with PIH have hyperreflexia and pitting edema and may have clonus too. Patients who go home should be warned about returning if symptoms occur which suggest progression to severe PIH – headache, increased edema, visual symptoms such as flashing lights, and pain in the epigastric or RUQ area.

Labs are helpful in the evaluation of PIH – serum LFTs, BUN/Cr and uric acid as well as 24-hour urine for protein is all use to determine severity of PIH. Patients with severe PIH warrant delivery to prevent the progression to eclampsia (seizures). Patients with mild PIH may be carefully monitored at home or in the hospital. The treatment is bedrest, preferably on the left side as it reduces compression of the aorta and vena cava, therefore lowering BP. A home BP monitor may be helpful for patients at home.

Q7. What is the definition of PROM? How is it confirmed? What is your management plan?

Definition = ruptured membranes before 36 weeks (term)

Confirmation is by a sterile speculum exam and testing for amniotic fluid. A sterile speculum exam uses the same technique as a normal speculum exam however to prevent possible infection of the amniotic fluid a sterile speculum, sterile gloves and sterile swabs are used. During the exam, pooling of clear watery fluid in the lowest point of the vagina which is usually below the cervix, suggests ruptured membranes. The fluid is swabbed with sterile swabs to test for amniotic fluid.

The diagnosis of ruptured membranes is made when the fluid on a Nitrazine test strip turns the strip blue and when a pattern called ferning is seen on a slide viewed under a microscope. (See Figure 1 below)

Plan: Await labor. Once PROM occurs, labor is not stopped even in the case of prematurity because of the risk of chorioamnionitis which is a serious infection for the patient and fetus. Depending on the gestational age and availability of neonatal care, patients may need to be transferred to a hospital with a neonatal intensive care unit and transfers are best done before labor starts.

Patients are usually admitted and assessed daily to make sure they are not becoming infected. If evidence of infection occurs (increased WBC, fever, and tender uterus) then labor is induced.

Figure 1 -Ferning as seen under a microscope

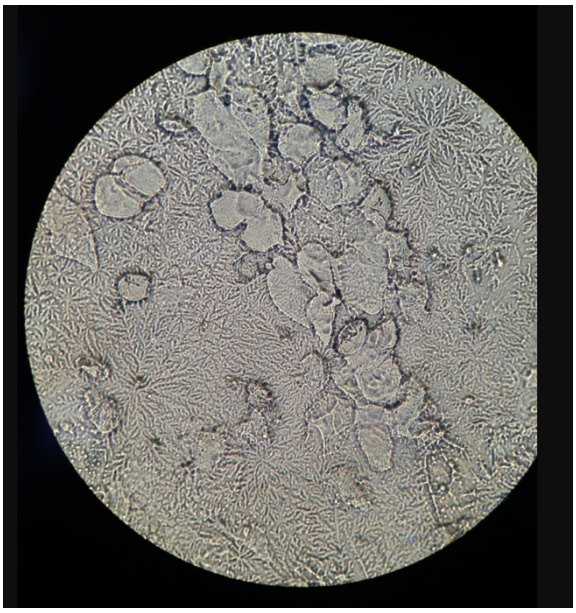

Credit: Nphilli1, CC BY-SA 3.0 <https://creativecommons.org/licenses/by-sa/3.0>, via Wikimedia Commons